



Brief report

The measurement of regional cerebral blood flow during glossolalia: A preliminary SPECT study

Andrew B. Newberg^{a,b,*}, Nancy A. Wintering^{a,b}, Donna Morgan^a, Mark R. Waldman^b

^a*Division of Nuclear Medicine, Department of Radiology, University of Pennsylvania Medical Center,
110 Donner Building, 3400 Spruce Street, Philadelphia, PA 19104, United States*

^b*Center for Spirituality and the Mind, University of Pennsylvania, Philadelphia, PA, United States*

Received 9 May 2006; received in revised form 20 July 2006; accepted 25 July 2006

Abstract

Glossolalia (or “speaking in tongues”) is an unusual mental state that has great personal and religious meaning. Glossolalia is experienced as a normal and expected behavior in religious prayer groups in which the individual appears to be speaking in an incomprehensible language. This is the first functional neuroimaging study to demonstrate changes in cerebral activity during glossolalia. The frontal lobes, parietal lobes, and left caudate were most affected.

© 2006 Elsevier Ireland Ltd. All rights reserved.

Keywords: Glossolalia; Cerebral blood flow; Single photon emission tomography

1. Introduction

Glossolalia, sometimes referred to as “speaking in tongues,” is an unusual mental state associated with specific religious traditions. The individual appears to be speaking in an incomprehensible language over which he or she claims to have no control. Yet, the individual perceives glossolalia to have great personal meaning. The individual also describes a lack of voluntary control over the vocalizations. Studies have shown that the vocalizations, which often are part of singing, are not related to any clear linguistic structure (Samarin, 1972). It is unclear whether glossolalia is

related to psychopathology (Hine, 1969; Lovekin and Malony, 1977), and one study suggested that abnormal temporal lobe activity could be a possible cause of glossolalia (Persinger, 1984). Since there are no imaging studies of this phenomenon, we wanted to determine if glossolalia was associated with specific changes in cerebral activity.

We present the ^{99m}Tc-Bicisate (Bristol Myers Squibb, N. Billerica, MA) SPECT data from five practitioners of glossolalia. We compared glossolalia to a religious singing state since the latter is similar except that it involves actual language (English). The SPECT technique used in this study measures regional cerebral blood flow (CBF) that correlates closely with cerebral activity. This technique was previously validated (Newberg et al., 2005) and also used in our similar study on meditation (Newberg et al., 2001).

We tested several hypotheses regarding glossolalia: (1) it is known that the frontal lobes are involved in

* Corresponding author. Tel.: +1 215 662 3014; fax: +1 215 349 5843.

E-mail address: andrew.newberg@uphs.upenn.edu
(A.B. Newberg).

willful control of behaviors (Frith et al., 1991; Pardo et al., 1991). We hypothesized that glossolalia, associated with the perceived loss of intentional control, would be associated with decreased activity in the frontal lobes compared with singing; (2) we previously argued that in practices such as meditation, there is decreased activity in the superior parietal lobe (SPL) because of the altered sense of self (Lynch, 1980; Newberg et al., 2001). This is not described in glossolalia, and thus we expected no such decrease; (3) glossolalia is a highly active state, and hence we expected increased CBF in the thalamus related to overall increased cerebral activity; (4) we expected increased activity in the limbic areas such as the amygdala since glossolalia is a very emotional state.

2. Methods

2.1. Subjects and imaging acquisition

We recruited five women ranging from 38 to 52 years with a mean of 45 years (both men and women perform glossolalia, but in our community, there is a preponderance of women). Each subject described herself as a Christian in a Charismatic or Pentecostal tradition who had practiced glossolalia for more than 5 years. All were active, stable members of their communities. On the study day, informed consent (approved by the Institutional Review Board) was obtained. Structured clinical interviews excluded current psychiatric conditions, without considering the practice of speaking in tongues. Thus, none of the subjects reported visual or auditory hallucinations, mood disorders, or exhibited any clear evidence of current Axis I or II disorders (American Psychiatric Association, 1994). It should be noted that one subject reported a history of substance abuse but had been abstinent for 4 years. In addition, subjects did not have any active neurological or medical conditions, or take medications that would affect cerebral function. Subjects had to have a negative pregnancy test. Initially, an intravenous cannula (IV) was placed in one arm with a long IV line to permit relatively free range of movement, needed for singing and glossolalia.

The subject began singing in the room while standing, with her eyes closed, matching her condition during glossolalia. Earphones were used to play music to sing and to perform glossolalia (the same music was used for both). The subject sang for 5 min at which time she was injected through the IV with 7 mCi of ^{99m}Tc -Bicisate. The subject continued singing for 15 min, at which time the singing state was terminated and she was brought to the SPECT scanner for a 40-min scan.

Images were acquired on a Picker-Prism 3000 XP (Picker Inc, Cleveland, OH) triple-headed scanner using high resolution fan beam collimators. Projection images were obtained at 3° angle intervals on a 128 × 128 matrix (pixel size 3.56 mm × 3.56 mm) over 360°. SPECT images were reconstructed using filtered backprojection, followed by a low pass filter and 1st order Chang attenuation correction.

Following the “singing” scan, the subject returned to the room to perform glossolalia. It began with the music playing and the person initially singing, and then relatively quickly entering into the glossolalia state (usually within 5 min). Once the subject was observed performing glossolalia for 5 min, she was unobtrusively injected with 25 mCi of ^{99m}Tc -ECD. The subject continued to perform glossolalia for 15 min and then the session was ended. The subject was then scanned (“glossolalia” scan) for 30 min using the same imaging parameters as above.

It should be noted that we observed all subjects to ensure that the two conditions (singing and glossolalia) were as similar as possible in terms of patient vocalization and motion with the exception of the glossolalia itself. Both conditions involved listening to music and singing, which was voluntary and performed while listening to gospel music. The glossolalia was perceived to be non-voluntary by the subjects. Subjects were standing throughout both conditions and were moving both their arms and legs in a similar rhythmic manner during both conditions. We did not observe any particular changes in the motor cortex, which suggests that the patient’s motion was not significantly different between the two states. The phonemic structure was different between the two conditions since the singing was associated with clear grammatical sentences, although they were often brief utterances such as “Praise God” or “Thank you, Jesus” in both conditions. The phonemic structure during the glossolalia state was variable with periods of increased and decreased intensity, volume, and speed, although certain “phrases” were repeated a number of times.

2.2. Image analysis and statistics

The singing and glossolalia scans were resliced and coregistered. A previously validated template consisting of regions of interest (ROIs) corresponding to major cortical and subcortical structures was placed over the singing scan (Resnick et al., 1993). Each ROI was adjusted manually to achieve the best fit. ROIs were then copied directly onto the glossolalia scan. Count values for the glossolalia scans were obtained by

determining the counts in each ROI and subtracting the number of counts in the same ROI on the singing scan (decay corrected to the midpoint of the two scans). Counts per pixel in each ROI were normalized to whole brain activity yielding a CBF ratio. A percentage change was calculated for each region. A laterality index (LI) representing the percentage difference between the right and left side was also calculated.

CBF ratios were compared between the glossolalia and singing state using a paired *t*-test (Minitab Statistical Software, 2000). The LI for each homologous pair of ROIs in the singing and glossolalia states was compared using paired *t*-tests as well. Our results were hypothesis driven so comparisons were only tested for the major structures of the frontal, temporal, and parietal lobes, as well as the amygdala, hippocampus, striatum, and thalamus, and thus a correction for multiple comparisons was not performed.

3. Results

The data between the glossolalia and singing state revealed several significant rCBF differences (see Table 1 and Fig. 1). There were significant decreases in the prefrontal cortices, left caudate and left temporal pole while there were increases in the left superior parietal lobe (SPL) and right amygdala. There was a significant negative correlation ($R=-0.90$, $P=0.03$) between the singing and glossolalia thalamic LI, indicating that the more the thalamic activity was asymmetric to begin with, the more the asymmetry reversed during glossolalia.

4. Discussion

References to speaking in tongues—or glossolalia, as it is technically called—can be found in the Old and New Testaments, but until the 20th Century, only brief

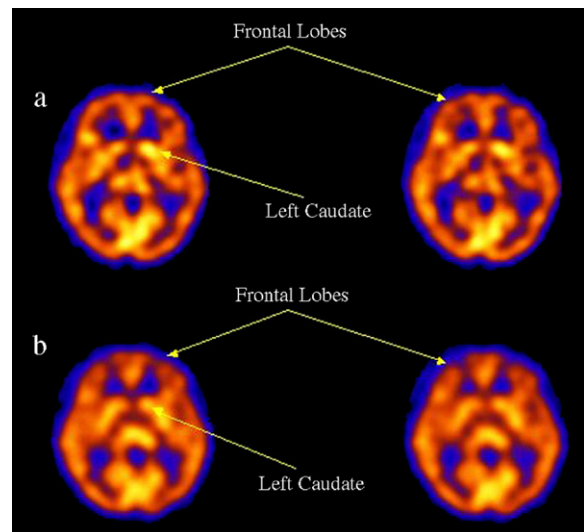


Fig. 1. This figure shows two transaxial slices of the singing state (a) and the glossolalia state (b) with rCBF represented as red>yellow>green>blue. These images demonstrate decreased rCBF during glossolalia in the frontal lobes bilaterally. Also, there is a marked decrease in blood flow in the left caudate (as indicated by the arrow) during glossolalia compared with the singing state.

references have been made. Its more recent rise in use is believed to have originated at the Azusa Street Mission when a woman named Agnes Ozman first began to speak in tongues and initiated the charismatic movement in the United States (Balmer, 2001). More recently, researchers at the University of London identified two distinct forms of glossolalia (Grady and Loewenthal, 1997). The first, which we studied in this report, is the more dramatic form, involving singing, vocal utterances, and ecstatic bodily experiences. However, the researchers found that many practitioners engage in a gentler, almost silent glossolalic prayer that is associated with calm, pleasant emotions.

Originally, it was thought that glossolalia was related to some form of psychopathology by the biomedical community. However, the limited number of reported studies have suggested that people who speak in tongues show no differences in personality traits from other population groups—no increases in depression, anxiety, mania, or psychosis (Hine, 1969; Richardson, 1973). In fact, only a small percentage of mentally ill people exhibit glossolalia, and when they do, the hallucinations often have a religious content (Hempel et al., 2002). One recent study involved nearly a thousand clergy members of a British evangelical group. The researchers found that the 80% who practiced glossolalia had greater emotional stability and less neuroticism (Francis and Robbins, 2003). Other studies have not supported the finding that glossolalia has health benefits, but neither did they find

Table 1
Assessing the difference between rCBF during singing and glossolalia based on ROI analysis

Part of the brain	<i>P</i> -value	Singing mean	Glossolalia mean	Percent change	Standard deviation
Right DLPFC	0.003	1.27	1.15	9.4	0.09
Right amygdala	0.07	0.87	0.94	8.0	0.09
Left DLPFC	0.01	1.30	1.18	9.2	0.10
Left caudate	0.002	1.33	1.08	18.9	0.08
Left dorsomedial cortex	0.04	1.32	1.24	4.0	0.10
Left temporal pole	0.009	0.95	0.89	6.3	0.04
Left superior parietal	0.009	1.13	1.24	9.7	0.05

any negative psychological effects (Louden and Francis, 2001).

The present study is the first we are aware of that has evaluated changes in cerebral activity during the practice of glossolalia. Regarding our hypotheses, we observed decreased activity in the prefrontal cortices during the glossolalia state. This finding was clearly distinct from our previous study of meditation using the same imaging technique (Newberg et al., 2001). Neuroimaging studies have also shown increased frontal lobe activity during attention-focusing tasks (Frith et al., 1991; Pardo et al., 1991). It is interesting that the frontal lobes showed decreased perfusion during glossolalia, but this is consistent with the subjects' description of a lack of intentional control over the performance of glossolalia. A left lateralization in the frontal lobes might be expected since singing and glossolalia are related to language functions. While such a lateralization was not robust, the left hemispheric structures appeared to have significant decreases that were not observed in the right hemisphere. However, the lack of a clear lateralization in the frontal lobes suggests that the expressive language parts of the brain may not be as directly affected by glossolalia as might be expected.

Our second hypothesis predicted no change in the SPL. We have previously argued, and found, decreased activity in the SPL during meditation in which there is a described loss of the sense of self. However, glossolalia was not associated with a loss of the sense of self and there were no significant decreases in the SPL.

We did not observe the hypothesized increase in thalamic activity. However, there was a shift in thalamic LI between the singing and glossolalia scans. It is not clear what such a finding may represent from a physiological perspective, but the thalamus is a major cortical and cortical–subcortical relay, serving as a gating function of neuronal information. This might be important for altering the sense of control in which practitioners no longer feel as if they are willfully making the vocalizations.

Our fourth hypothesis was that there would be increased activity in the limbic structures, and there was a trend towards increased activity in the right amygdala. An earlier report described seizure-like electrical activity in a subject during prolonged glossolalia (Persinger, 1984). The marginally increased activity observed in our study does not elucidate the exact relationship between the limbic system and glossolalia, nor does it rule out the possibility of seizure activity. The significant decrease in the left caudate is of uncertain significance but may relate to the altered emotional activity during glossolalia.

Potential confounding problems with this study include the fact that the subjective sense reported during glossolalia is difficult to measure. However, it is easy to observe when an individual is performing glossolalia, so there is little doubt that the injection of Bicisate occurred during that state. Future studies should also evaluate the phonemic structure of the vocalizations in glossolalia to understand the basic units of this vocalization and to compare these to imaging results. This study measured CBF at a single point during glossolalia, at a relatively early time point. Future studies might determine whether there are different changes after a longer time performing glossolalia. The study has a limited number of subjects since it is difficult to find experienced practitioners willing to perform glossolalia in a laboratory setting. While this complicates the statistical analysis, the number of subjects was sufficient to reveal statistically significant results.

The results from this preliminary study have begun to elucidate the neurophysiological correlates of glossolalia. That there were changes in several brain structures suggests that there is complex brain activity during this unusual practice. Future studies should explore the cerebral correlates of glossolalia in a larger sample incorporating physiological and neurophysiological measures in addition to a more elaborate analysis of the phonemic structure of glossolalia.

References

- American Psychiatric Association, 1994. *Diagnostic and Statistical Manual of Mental Disorders*, fourth edition. APA, Washington, DC.
- Balmer, R., 2001. *Religion in 20th Century America*. Oxford University Press, Oxford.
- Francis, L., Robbins, M., 2003. Personality and glossolalia: a study among male evangelical clergy. *Pastoral Psychology* 51, 5.
- Frith, C.D., Friston, K., Liddle, P.F., Frackowiak, R.S.J., 1991. Willed action and the prefrontal cortex in man. A study with PET. *Proceedings of the Royal Society of London* 244, 241–246.
- Grady, B., Loewenthal, K.M., 1997. Features associated with speaking in tongues (glossolalia). *British Journal of Medical Psychology* 70, 185–191.
- Hempel, A.G., Meloy, J.R., Stern, R., Ozone, S.J., Gray, B.T., 2002. Fiery tongues and mystical motivations: glossolalia in a forensic population is associated with mania and sexual/religious delusions. *Journal of Forensic Sciences* 47, 305–312.
- Hine, V.H., 1969. Pentecostal glossolalia: toward a functional reinterpretation. *Journal for the Scientific Study of Religion* 8, 212–226.
- Louden, S.H., Francis, L.J., 2001. Are Catholic priests in England and Wales attracted to the charismatic movement emotionally less stable? *British Journal of Theological Education* II, 65–76.
- Lovekin, A., Malony, H.N., 1977. Religious glossolalia: a longitudinal study of personality changes. *Journal for the Scientific Study of Religion* 16, 383–393.

- Lynch, J.C., 1980. The functional organization of posterior parietal association cortex. *Behavioral and Brain Sciences* 3, 485–499.
- Newberg, A.B., Alavi, A., Baime, M., Pourdehnad, M., Santanna, J., d'Aquili, E.G., 2001. The measurement of regional cerebral blood flow during the complex cognitive task of meditation: a preliminary SPECT study. *Psychiatry Research: Neuroimaging* 106, 113–122.
- Newberg, A.B., Saffer, J., Farrar, J., Pourdehnad, M., Alavi, A., 2005. Stability of cerebral blood flow measures using a split-dose technique with ^{99m}Tc-exametazime SPECT. *Nuclear Medicine Communications* 26, 475–478.
- Pardo, J.V., Fox, P.T., Raichle, M.E., 1991. Localization of a human system for sustained attention by positron emission tomography. *Nature* 349, 61–64.
- Persinger, M.A., 1984. Striking EEG profiles from single episodes of glossolalia and transcendental meditation. *Perceptual and Motor Skills* 58, 127–133.
- Resnick, S.M., Karp, J.S., Tretsky, B.I., Gur, R.E., 1993. Comparison of anatomically defined versus physiologically based regional localization: effects on PET-FDG quantitation. *Journal of Nuclear Medicine* 34, 201–208.
- Richardson, J.T., 1973. Psychological interpretations of glossolalia: a reexamination of research. *Journal for the Scientific Study of Religion* 12, 199–207.
- Samarin, W., 1972. Variation and variables in religious glossolalia. In: Haymes, D. (Ed.), *Language in Society*. Cambridge University Press, Cambridge.